

## Case Report

# Permanent His bundle pacing using a Biotronik stylet-driven lead: feasibility and early outcomes from a single centre

Brian Vezi, Ajjjola Olujimi, Marcus Ngatcha, Aime Bonny, Justin Ragadu

### Abstract

His bundle pacing (HBP) has been shown to be a good alternative to conventional cardiac resynchronisation therapy (CRT) and may theoretically provide an additional benefit where CRT has a response deficit of at least 30%. HBP requires mapping and identification of the His bundle, and to this purpose the lead delivery is challenging. This first-reported case series from Africa shares early experience with different pacing indications (complete heart block and pre-existing right ventricular pacing; heart failure with left bundle branch block) for using a standard 5.6F, Solia S 60, IS-1, ProMRI bipolar pacing lead and an 8.7F Selectra 3D introducer guide, 32–39-cm working length with 40/55/65-mm proximal radii (Biotronik). These cases highlighted the importance of appropriate programming when implanting HBP and of assessing the conduction system to predict patients who might benefit from HBP and additional left ventricular lead implant. The Biotronik Solia lead and delivery guide were found to be feasible and reliable in these cases. The Biotronik conduction system pacing tools were used with good acute outcomes in patients with different pacing indications.

**Keywords:** His bundle pacing, selective, non-selective

Submitted 5/11/21, accepted 28/5/22

*Cardiovasc J Afr* 2022; online publication

www.cvja.co.za

DOI: 10.5830/CVJA-2022-026

### Busamed Gateway Private Hospital, Umhlanga, South Africa

Brian Vezi, MB CHB, FCP (SA), Cert Cardio (SA), MPharm Med Pretoria, Electrophysiology (Ottawa, Canada), brian.vezi@gmail.com

### Cardiac Arrhythmia Center, University of California, Los Angeles, USA

Ajjjola Olujimi, MD, PhD

### Homeland Heart Center, Douala and District Hospital of Bonassama, University of Douala, Douala, Cameroon

Marcus Ngatcha, MD  
Aime Bonny, MD

### Durban University of Technology, Durban, South Africa

Justin Ragadu, N Diploma, B Tech

His bundle pacing (HBP) has been shown to be a good alternative to conventional cardiac resynchronisation therapy (CRT).<sup>1,2</sup> Right ventricular-only pacing (RVOP) in patients with bradycardia may be deleterious, especially with a high right ventricular (RV) pacing burden, which is expected in complete heart block (CHB).<sup>3</sup> HBP may theoretically provide an additional benefit where CRT has a response deficit of at least 30%, by maintaining normal antegrade conduction via the His–Purkinje system rather than the sustained electropathy observed in CRT.<sup>1,2,4</sup> CRT using HBP in lieu of the left ventricular (LV) lead has no need for coronary sinus cannulation.

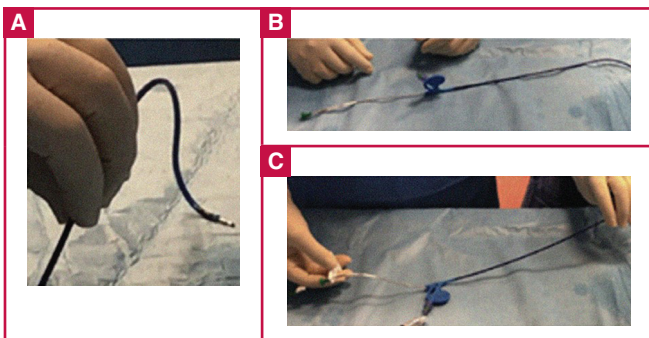
HBP may correct distal left bundle branch block (LBBB) if pacing is distal to the lesion site.<sup>1,4</sup> RVOP has been shown to result in cardiomyopathy (CM), heart failure (HF) and atrial fibrillation (AF).<sup>2</sup> There are two electrocardiogram (ECG) morphologies in HBP, selective (S-HBP) and non-selective (NS-HBP).<sup>5</sup> In CHB or post-atrioventricular (AV) node ablation, NS-HBP may be preferred as a back-up as the local RV myocardium remains captured in case of loss of HBP.

HBP requires mapping and identification of the His bundle. The lead delivery is challenging and may result in dislodgment.<sup>6</sup> Until recently, only Medtronic supplied a screw-in lumenless lead (SelectSecure 3830) and two delivery guides (Preshaped catheter C315HIS and SelectSite catheter C304-L69).<sup>7</sup> The small diameter and floppy design of the exposed screw in the Medtronic system make it easier to screw in the lead, even when the sheath is not perpendicular to the target site. However, this can represent a significant limitation since the lead can be screwed in a target site only if it can be accessed by the delivery sheath, and when the target site is in the intraventricular portion of the membranous septum, the anterior and septal leaflet of the tricuspid valve can make the His bundle inaccessible to these sheaths.<sup>8</sup> Furthermore, the lead requires active fixation by manual turning of the lead and this may result in low acceptance in inexperienced hands.

In Africa, where resources are strained, the cost of the Medtronic HBP guide and lead may be prohibitive. The Biotronik HBP lead is the same as the conventional lead used for right atrial and ventricular pacing and has been used recently without an outer sheath or guide.<sup>9</sup> The combination of the stylet-driven Solia S 60 lead with the Selectra 3D can enable the lead to reach almost all desired regions (Fig. 1).<sup>7,8</sup>

### Case reports

Lead stylets expedite tissue contact and stability during implant and are familiar to cardiac pacing physicians. We report on three



**Fig. 1.** A: The delivery catheter Selectra 3D (Biotronik SE & Co. KG, Berlin, Germany), with a double curve to all septal positioning. Note the standard screw lead exposed at the end of the delivery. B: The standard stylet-driven 6F lead inside the Selectra catheter. C: The standard stylet-driven 6F lead inside the Selectra catheter. Note at the tip of the lead the fixation tool to screw the retractable helix.<sup>7</sup>

cases with different pacing indications. Here we share our early experience using a standard 5.6F, Solia S 60, IS-1, ProMRI bipolar pacing lead and an 8.7F Selectra 3D introducer guide, 32–39-cm working length with 40/55/65-mm proximal radii (Biotronik).

In all patients, the implant technique was similar. A venogram was performed to elucidate the cephalic/axillary/subclavian vein anatomy. Two to three guidewires were passed down to the inferior vena cava to ensure venous anatomy and thus avoid arterial puncture. The active fixation atrial lead was first placed

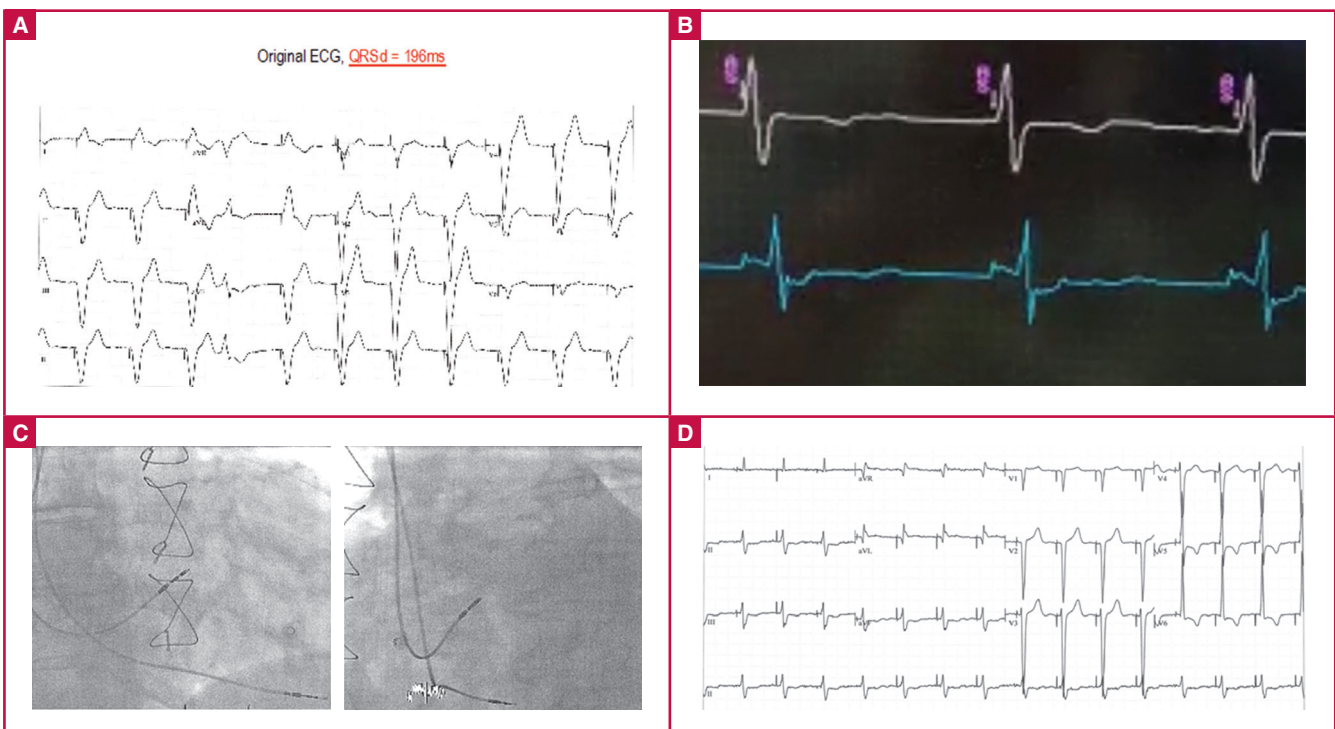
at the RV apex as a back-up pace lead in case of inadvertent CHB during His mapping. Post HBP, the atrial lead was repositioned from the RV apex to the right atrium. If the QRS duration (QRSd) was reduced by at least 20 ms or 20%, the LV lead was not implanted, and the third guidewire was removed. If the QRSd was not shortened by the set pre-implant expectation, the LV lead was implanted as per the His-optimised CRT (HOT-CRT) technique.<sup>10</sup>

His mapping was performed in a unipolar configuration and done prior to active fixation, as is generally performed for HBP. In the first two patients, the stylet was not curved distally. The desired ECG was a small 'A', clear His and large 'V'. The Solia S60 lead helix was extended using the fixation tool (10 to 15 turns) to expose and anchor the distal helix, followed by an additional six to nine clockwise turns on the fixated stylet guide to build up inner coil tension on the helix. Lastly the lead body was turned clockwise (five to six turns) for final fixation of the lead.

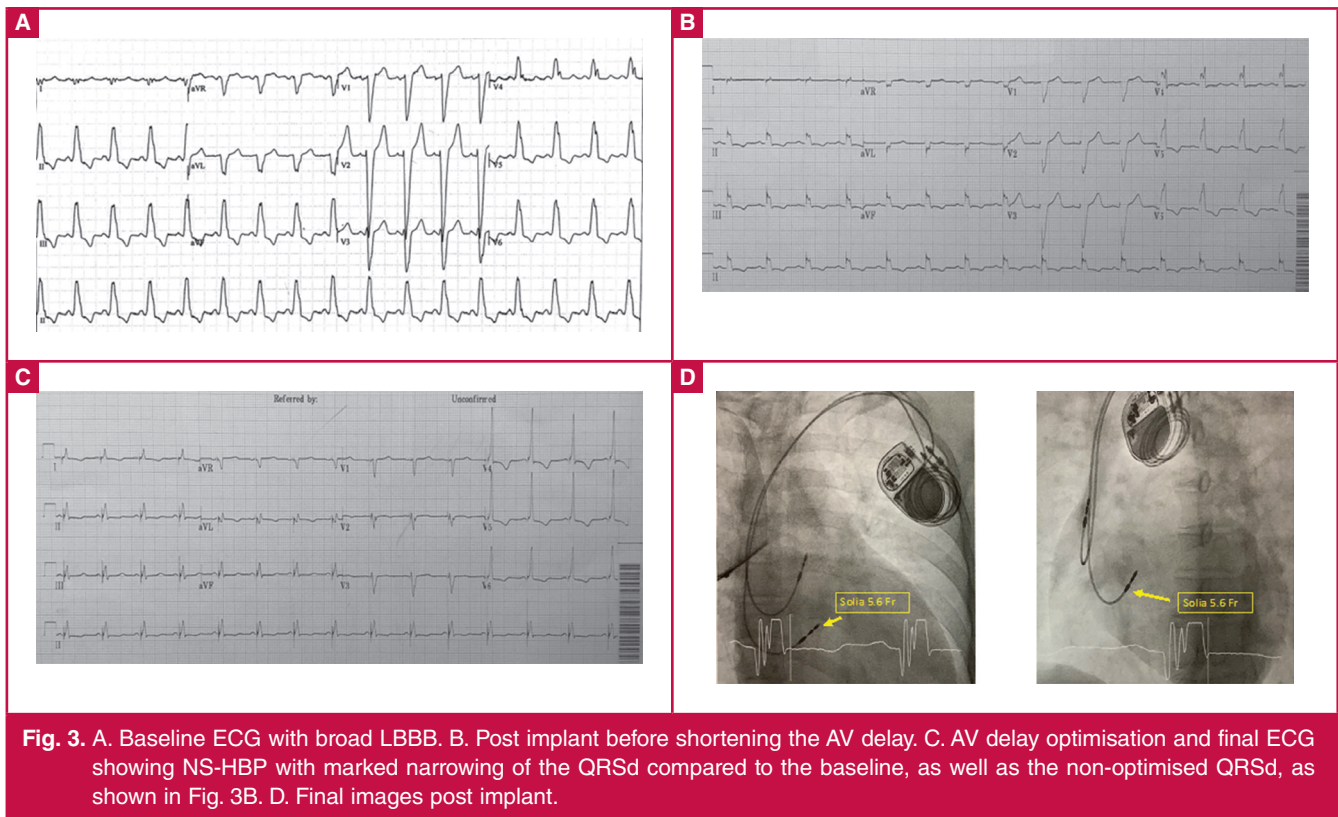
The stylet guide was removed and the stylet pulled back by approximately 10 cm to avoid inadvertent dislodgement during sheath removal. The guide was then retrieved approximately 2–3 cm, exposing the lead tip. If the lead remained in place, a marker of acute stability, then the guide was slit and removed, followed by total withdrawal of the stylet.

### Patient 1

This was a 76-year-old male patient with CHB and pre-existing RVOP (VVIR), a paced QRSd of 196 ms (Fig. 2A), previous coronary artery bypass grafting, chronic AF and HF and New York Heart Association (NYHA) class III on optimal



**Fig. 2.** A. Baseline paced (VVIR) ECG, QRSd = 196 ms. B. Current of His bundle injury during deployment of Biotronik Solia S pacing lead at the His bundle. C. Biotronik Solia S pacing lead at the His bundle and the pre-existing RV lead. D. NS-HBP post-implant, QRSd = 106 ms.



**Fig. 3.** A. Baseline ECG with broad LBBB. B. Post implant before shortening the AV delay. C. AV delay optimisation and final ECG showing NS-HBP with marked narrowing of the QRSd compared to the baseline, as well as the non-optimised QRSd, as shown in Fig. 3B. D. Final images post implant.

medication. The left ventricular ejection fraction (LVEF) was 15% at first consultation. He had a ventricular escape of 36/min. He underwent NS-HBP with a QRSd of 115 ms (Fig. 2B). The old RV lead was connected to the RV port and the His lead to the atrial port (Fig. 2C).

Post-implant QRSd was 106 ms (Fig. 2D). Four weeks later the LVEF improved from 14 to 28% and NYHA from class III–IV to II. The His-lead parameters were: R wave = 1.4 mV, impedance = 374 Ω, threshold = 2.5 V @ 1.00 ms

**Patient 2**

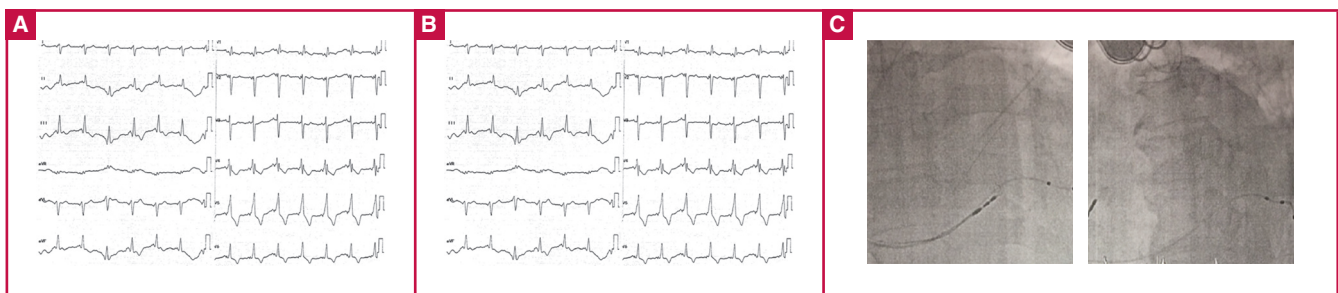
This patient was a 45-year-old female with post-partum CM, HF with LBBB, QRSd = 156 ms, NYHA class III and LVEF of 25% in sinus rhythm. She underwent a CRT pacemaker (CRT-P) via the right atrium and HBP only (Fig. 3A).

Post implant, the QRSd was 130 ms with NS-HBP (Fig. 3B–D). The His-lead parameters were: HBP: R wave = 6.7 mV,

impedance = 351 Ω, threshold = 4.4 V @ 1.00 ms; RA: P wave = 2.0 mV, impedance = 556 Ω, threshold = 0.6 V @ 0.5 ms.

**Patient 3**

A 48-year-old male presented with HF with prolonged PR ± 208 ms due to dilated CM (Fig. 4A). He had LBBB with QRSd = 158 ms and left anterior hemiblock (LAHB) with axis deviation at -73°. During His mapping the His-ventricular (HV) was prolonged at 90 ms. The QRSd was reduced from 158 to 140 ms. This was not surprising as there was evidence of infra-Hisian disease (LAHB with QRS axis -73° and HV = 90 ms). The LV lead was therefore implanted and the QRSd was further reduced to 124 ms (Fig. 4B). The other reason to implant the LV lead was the observed prolonged HV interval as well as the left-axis deviation, alluding to the infra-Hisian disease (Fig. 4C). The His-lead parameters were: R wave = 8.9 mV, impedance = 754 Ω, threshold = 1.0 V @ 1.00 ms.



**Fig. 4.** A. Baseline ECG with LBBB with atypical features, namely, Q in V5, S in V5–V6 and left-axis deviation. B. His and LV pacing simultaneously with QRSd = 124 ms. C. The right and left anterior oblique X-rays of patient 3.

### Key points

- The Biotronik Solia lead and delivery guide were feasible and reliable in the three cases observed here.
- The second patient highlighted the importance of appropriate programming when implanting HBP. The shortening of the AV delay is paramount to optimise biventricular resynchronisation.
- The third patient showed the importance of assessing the conduction system to predict patients who might benefit from HBP and additional LV lead implant, as per HOT-CRT evidence.

### Conclusion

This is the first reported cases series from Africa. The importance of HBP in resource-limited countries cannot be over-emphasised. In the cases of CRT, the dual-chamber box is often used for HBP, and one fewer lead is needed. In our three-case series, HBP using the Biotronik extendable/retractable active fixation lead supported by a luminal stylet was achievable without limitations or complications. The stylet-based HBP afforded good lead stability and tissue contact, as shown by the observable current of injury. The Biotronik conduction system pacing tools were used with good acute outcomes in patients with different pacing indications.

### References

1. Ajjola OA, Upadhyay GA, Macias C, *et al.* Permanent His bundle pacing for cardiac resynchronization therapy: initial feasibility study in lieu of left ventricular lead. *Heart Rhythm* 2017; **14**(9): 1353–1361.
2. Lustgarten DL, Crespo EM, Arkhipova-Jenkins I, *et al.* His-bundle pacing versus biventricular pacing in cardiac resynchronization therapy patients: A crossover design comparison. *Heart Rhythm* 2015; **12**(7): 1548–1557.
3. Sharma AD, Rizo-Patron C, Hallstrom AP, *et al.* Percent right ventricular pacing predicts outcomes in the DAVID trial. *Heart Rhythm* 2005; **2**(8): 830–834.
4. El-Sherif N, Amay-Y-Leon F, Schonfield C, *et al.* Normalization of bundle branch block patterns by distal His bundle pacing. Clinical and experimental evidence of longitudinal dissociation in the pathologic His bundle. *Circulation* 1978; **57**(3): 473–483.
5. Vijayaraman P, Dandamudi G, Zanon F, *et al.* Permanent His bundle pacing: recommendations from a multicenter His bundle pacing collaborative working group for standardization of definitions, implant measurements, and follow-up. *Heart Rhythm* 2017; **15**(3): 460–468.
6. Deshmukh P, Casavant DA, Romanyshyn M, *et al.* Permanent, direct His-bundle pacing: a novel approach to cardiac pacing in patients with normal His-Purkinje activation. *Circulation* 2000; **101**(8): 869–877.
7. Zanon F, Marcantoni L, Pastore G, *et al.* Left bundle branch pacing by standard stylet-driven lead: Preliminary experience of two case reports. *Heart Rhythm Case Rep* 2020; **6**(9): 614–617.
8. Zingarini G, Notaristefano F, Sphigi L, *et al.* Permanent His bundle pacing using a new tridimensional delivery sheath and a standard active fixation pacing lead: The telescopic technique. *J Cardiovasc Electrophysiol* 2021; **32**(2): 449–457.
9. James Kneller. His bundle pacing: new approach using stylet-supported pacing leads. *EP Lab Digest* 2018; **18**(8): 1.
10. Vijayaraman P, Herweg B, Ellenbogen KA, *et al.* His-optimized cardiac resynchronization therapy to maximize electrical resynchronization: a feasibility study. *Circ Arrhythm Electrophysiol* 2019; **12**(2): e006934.